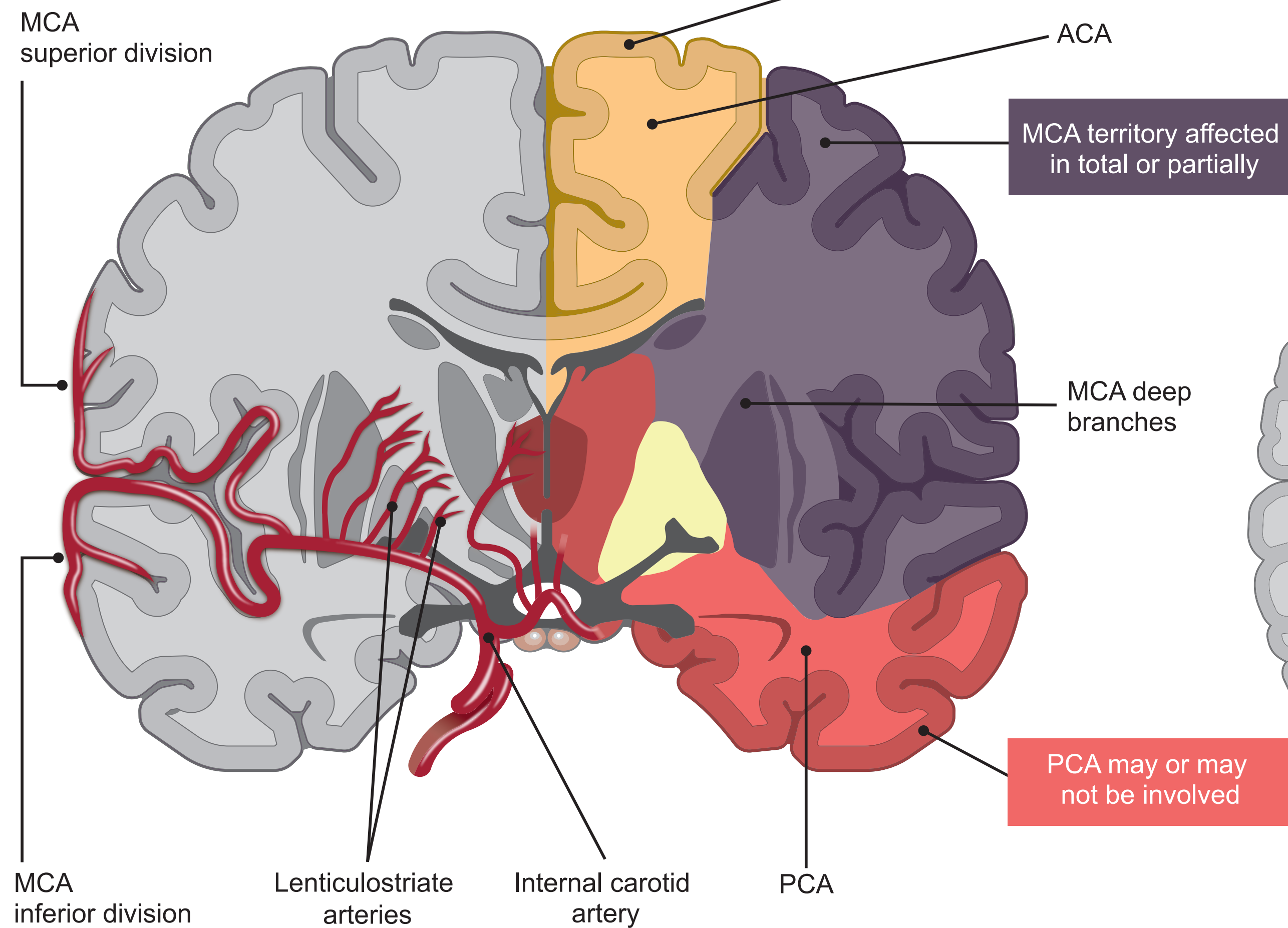


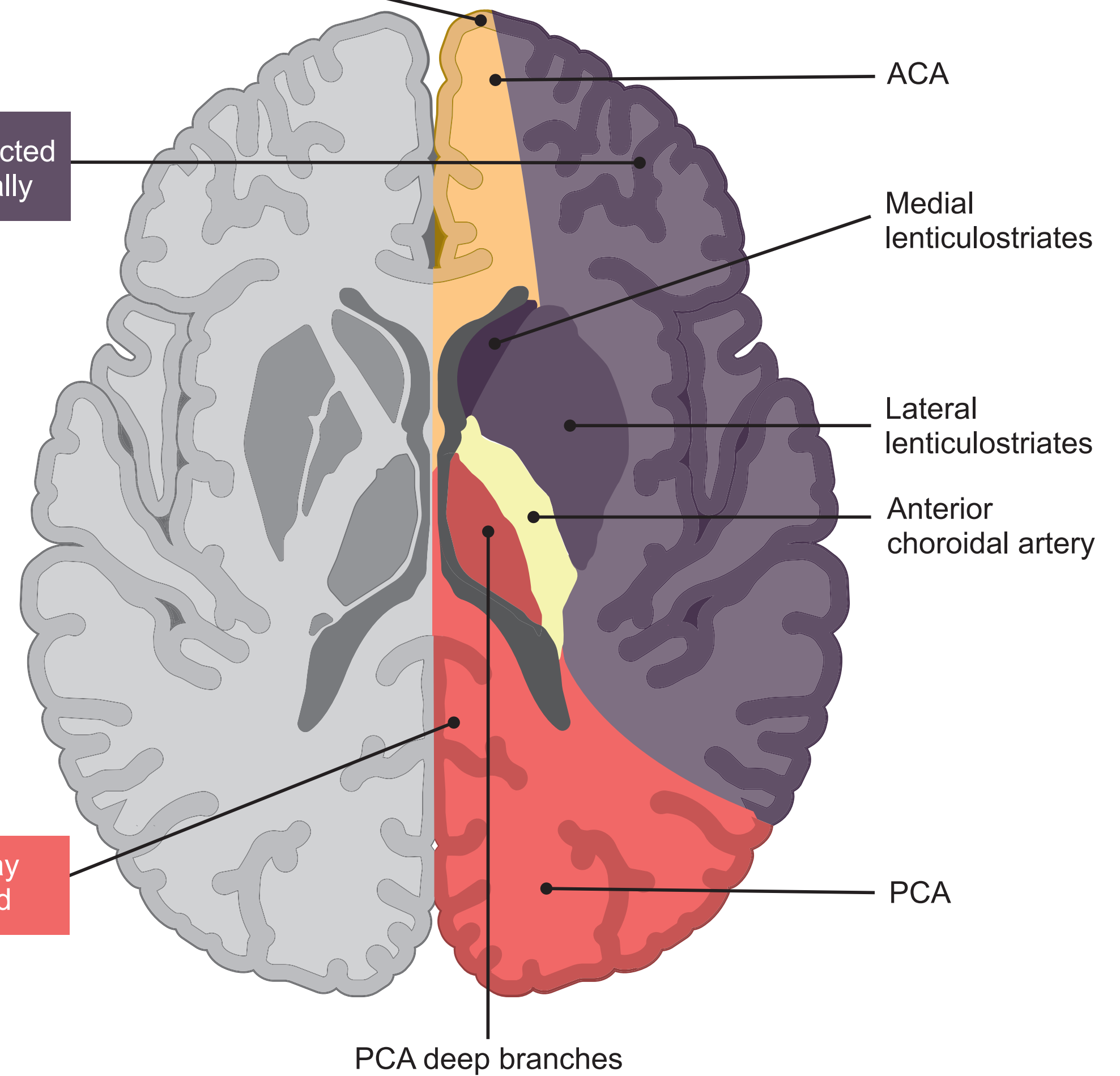
Cerebral Vascular Territories Involved in Large Hemispheric Infarction (LHI)¹⁻³

A severe and less common form of ischemic stroke

Coronal View



Axial View



1. Adapted from Teasell R Stroke Rehabilitation Clinician Handbook, 2020.
 2. Adapted from Torbey MT et al. Neurocrit Care. 2015;22:146-164.
 3. Adapted from Sinauer Associates 2002.

ACA=Anterior cerebral artery; MCA=Middle cerebral artery; PCA=Post cerebral artery.